

SSW
SSW
SSW
#

REPORTS

Vol. 13 No. 3

August 1991

**CHIARI MALFORMATION - WITH ORDER EFFECT
LOW/HIGH - WHEN THE TONSILS HANG LOW:
A CASE REPORT**

David W. Johnson
Department of Otolaryngology
University of Minnesota, Medical School
Minneapolis, MN 55455

History and Presenting Complaint

An 18 year old female patient was admitted to the Psychiatry service for depression. She was referred for audiological and otological evaluations because of a three year history of lightheadedness on arising, episodic spinning sensation on lying down, and buzzing tinnitus. Further questioning revealed a two year history of episodic posterior occipital headaches with increasing duration and severity, along with recent problems with numbness of the arms, problems listening, and difficulty judging distances (which caused her to stop driving a car). Her early history included an instance of a concussion, with unconsciousness, from a fall while roller skating as a child. She had a positive family history of both diabetes and hearing loss. The patient was on vestibular suppressants (because of a previous diagnosis of Meniere's disease) with poor control of the symptoms.

Audiologic Assessment

Audiometric testing revealed normal hearing, bilaterally, with good word discrimination, normal middle ear/eustachian tube function as shown by the tympanograms, and intact VIIIth nerve/brainstem function suggested by the acoustic reflex/decay patterns (and no wavy, on-off, reflex decay pattern associated with cerebellar involvement).

Figure 1 shows the basic audiometric results for this patient.

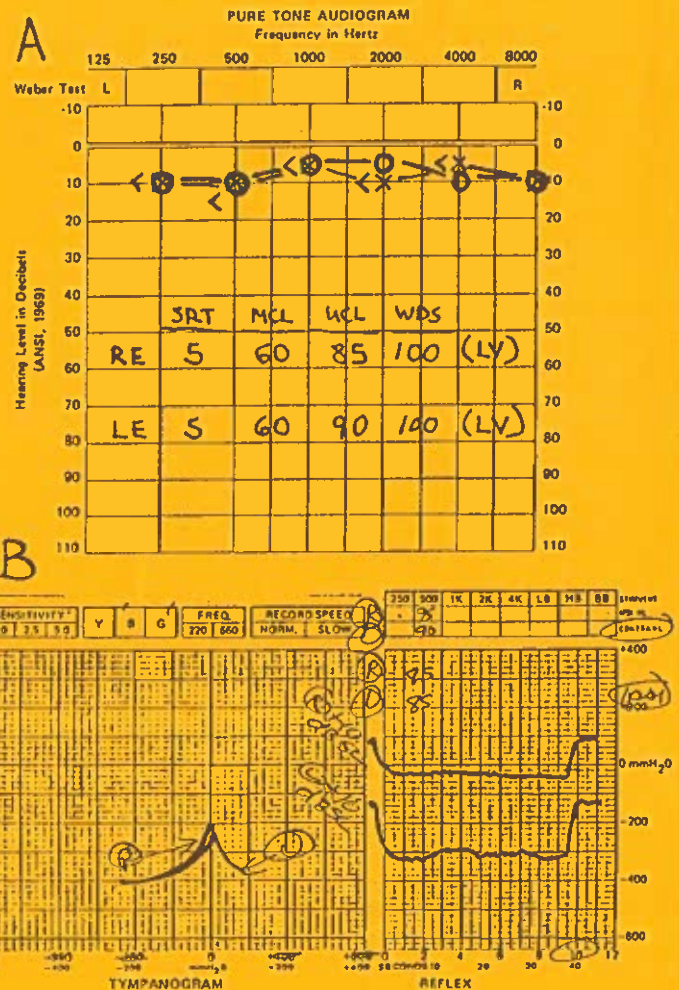


Fig.1. A) Shows puretone and basic speech results for an 18-year-old patient with Chiari malformations. These results are considered entirely normal. B) Shows immittance results. The tympanogram, acoustic reflexes and reflex decay were all normal.

All 40 items of the SSW EC list were administered and scored in the standard fashion. Figure 2 shows the SSW-Gram and the response bias information. The TEC was categorized as Mild (MI, MI, MI), based on the C-SSW scores. There were two reversals and a significant Order Effect low/high. The reversals and Order Effect low/high can be associated with cerebellar involvement (Katz, 1975). Furthermore, cerebellar cases may show a wide variety of error patterns that may mimic brain or brainstem disorders (Katz, 1978).

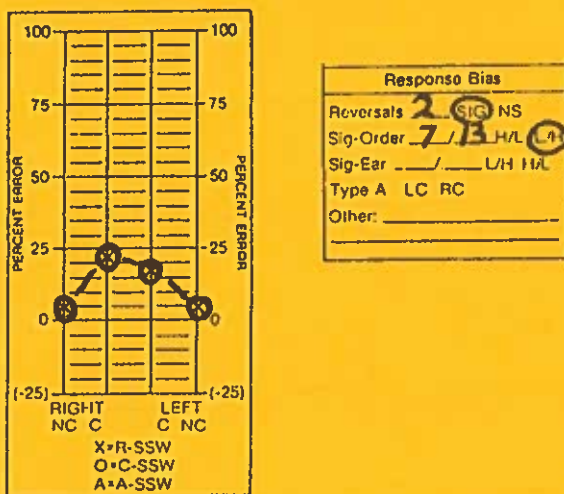


Fig.2. Shows the patient's SSW-gram and response bias information.

Otolaryngologic Assessment

The otolaryngologic evaluation of the head and neck were unremarkable. However, the Romberg and gait evaluations demonstrated dyskinetic lower extremities, supporting cerebellar disorder.

Radiologic Findings

Given the suggestion of cerebellar involvement on the lower extremity dyskinesia and the SSW, an MRI with contrast was ordered. Radiologic analysis

showed the cerebellar tonsils to be in a lowered position extending down to the mid-aspect of the posterior arch of C1. Mild tonsillar deformity consistent with mild Chiari II malformation was present. No other abnormalities were noted in the cerebellum, medulla or spinal cord. The brain and ventricular system appeared normal. Similarly, the cerebellopontine angles and internal auditory canals were normal.

The Disorder

Chiari malformation is a developmental defect that involves the cervicomedullary junction. In this disorder the soft tissue malformations involve the lower brainstem and cerebellum, elongating them and causing protrusion down into the cervical canal. During surgery the bony structure can be modified to relieve the pressure.

Baloh and Harker (1986) indicate that patients who have Chiari malformation may have complaints of dizziness. In addition subtle neurological signs and symptoms may be induced by a hydrocephalus that does not occur until young adult life. Episodic hearing loss, tinnitus and vertigo may be present in 25% to 75% of these patients. Eiles and Plester (1980) state that "Meniere's" patients may present with the same symptoms as the Chiari patients if the former have bony defects of the craniovertebral junction which presumably compresses the blood vessels and alter the cerebrospinal fluid circulation in the lower cerebellar region.

If there is a connection between Chiari malformation and Meniere's disease, perhaps subclinical cerebrospinal fluid build-up in Meniere's cases causes the perilymph/endolymph pressure changes. This could relate to the cerebrospinal fluid dynamics hypothesized by Goodhill (1980), in his attempt to explain sudden idiopathic hearing loss.

Surgical Findings

At the time of posterior fossa decompression, herniation of the cerebellar tonsils was noted, bilaterally, down to the level of C1.

Discussion

Dizzy patients are complex and generalizations based on a single case may not be fruitful. However, given this caution, some observations may be noteworthy. This patient was previously diagnosed as having Meniere's disease. Central findings are not unheard of in Meniere's cases. For example, Cafarelli et al. (1979) found 2 out of 12 Meniere's cases to have abnormal SSW scores. Nevertheless, because our evaluation showed normal hearing and continuing vertiginous complaints despite the use of vestibular suppressant drugs, there was reason to suspect that the problem was not Meniere's disease.

It should be noted that Chiari malformation may cause vertigo and hearing loss, though infrequently. In this case the patients complaints about listening difficulty could not be explained on the basis of a hearing loss.

While a MI SSW score could be due to an NAR cerebral dysfunction, it is not commonly associated with an Order Effect low/high (which is a posterior temporal sign that is much more likely to be found in AR cases). In AR cases we would expect MO or S TECs. With the greater peak of errors in the right ear, one could speculate that the left hemisphere was the site of such a presumed cerebral lesion. However, this was not too likely, because there was no indication or complaint about receptive language impairment in this college student. Rather, the problems with episodic dizziness when lying down and getting up would seem to be signs of dysfunction lower in the system.

Based on my SSW Workshop notes (Katz, 1975), the presence of the Order L/H and the reversals (that are rarely found in brainstem cases) made the cerebellum the most likely possibility (although not ruling out other sites).

It is also interesting to note that all aspects of the audiometric evaluation were entirely normal. Therefore, a central test was necessary to help account for the complaints. This makes me wonder if central testing should be

administered to more Meniere's-like cases, with or without hearing loss.

For users of the SSW test, several questions would appear appropriate. What is the significance of low/high Order Effect in dizzy patients when all other audiometric measures are within normal limits? When does an Order Effect low/high argue for an evaluation of the cerebellum with MRI of CT in active Meniere's cases? In light of the dearth of literature related to this matter, it would appear efficacious to attempt to collect a number of SSW cases with documented cerebellar maladies (e.g., Chiari malformation subjects). [Ergo, Jack Katz, are you ready for another national sample?]

REFERENCES

Baloh RW, Harker LA: Central vestibular disorders. In Harker (Ed), *Otolaryngology: Head and Neck Surgery* (vol 4), St Louis: Mosby Co, 1986, 3325-26.

Cafarelli MS, Nodar RH, Collard M, Larkins DA: SSW test results on patients with Meniere's disease. *SSW Reports*, 1, 3-5, 1979.

Eiles W, Plester D: Basilar impression: A differential diagnosis of Meniere's disease. *Arch Otolaryngol*, 106, 232-33, 1980.

Goodhill V: The "idiopathic group" and the "labyrinthine membrane rupture group" approaches to sudden sensorineural hearing loss. In Snow JB, *Controversy in Otolaryngology*, Philadelphia: Saunders Co, 1980, 12-22.

Katz J: SSW Workshop, Menorah Med Ctr, K.C., MO, July 21-23, 1975.

Editor's Note--

I found Dave Johnson's article most interesting and would be happy to help collect information dealing with cerebellar cases. If you have a verified cerebellar case (with or without an Order Effect) it would be of great interest to share.

I noticed the Order Effect L/H in my first 2 cerebellar cases back in the 1960s, so I tried to follow this lead to see the trend. Obviously in 1975 I was still mentioning this potential sign at SSW Workshops. However, over the years I came across a few (perhaps more?) cerebellar cases who did not have this response bias, so I mentioned it less and less over time and with less and less confidence.

From time to time audiologists have sent me the results of cases in which patients with cerebellar lesions did indeed have the Order L/H, but I do not know how representative it is. So, I'm reasonably sure that this is a possible result, but I am not sure at this time how to differentiate these cases from the AR cases with the same sign. Perhaps this sign is associates with a certain locus of cerebellar lesion, or possibly it is just an artifact of some sort. Whatever it is I think that this patient was no doubt benefited by Dave's alertness and wonderful memory. I will go through my files and see how many cerebellar cases there are and then provide a summary in an up coming SSW Reports.

LETTER TO THE EDITOR: ON BENDECTIN

Dear Editor:

Among those who have been referred to our Center for Central Auditory Processing testing are three (3) children whose mothers' took Bendectin (Debendox) while they were pregnant. Bendectin is an anti-nausea drug that was often prescribed for pregnant women. Now there is a growing literature (I have a list of 58 articles) about this drug and the possibility that it might cause birth defects. The drug was cleared in the courts when law suits were brought, but it is no longer prescribed.

Because of the great concern that has been expressed about this drug in causing birth defects, I was not too surprised to find that these children had evidence of CAP problems. What I

found most interesting and surprising was that all three children exhibited a Type A pattern on the SSW.

I thought that the readers of SSW Reports would be interested in this finding. I would be interested if other audiologists have found similar results when testing these children.

Susan M. Brandner, Senior Audiologist
Speech and Hearing Department
The Medical Center at Princeton
Princeton, NJ 08540-3213

CAN'T UNDERSTAND IN NOISE: A CASE

Darrel Feaks, M.S.
Millfort Clinic
Eau Claire, WI 54702-1510

Probably every audiologist has had a patient complain that he or she could not understand speech in a background of noise, only to find that there was no hearing loss. What then? This is a pretty routine case, but I haven't seen many of these cases in SSW Reports, so this will make the record more complete.

A 50-year-old woman was referred for a hearing evaluation because of considerable difficulty understanding speech in the presence of background noise. The patient reported a history of chronic earaches as a child and difficulty in school with memory, following directions and in reading comprehension.

Audiometric results demonstrated normal hearing for puretones (≤ 10 dB at all frequencies). Tympanograms were normal and ipsilateral acoustic reflexes were present. There was no tone decay and recorded W-22 discrimination scores were 100% in each ear.

During SSW testing the patient's 18 errors were all dK's (she did not have any idea what the words were). Some of her responses were quite delayed. Her 8 CNs were: 0 2 2 0 1 12 1 0. So there was a whopping Type A-LC and there were 2 reversals. Fig.1 shows the SSW-gram.

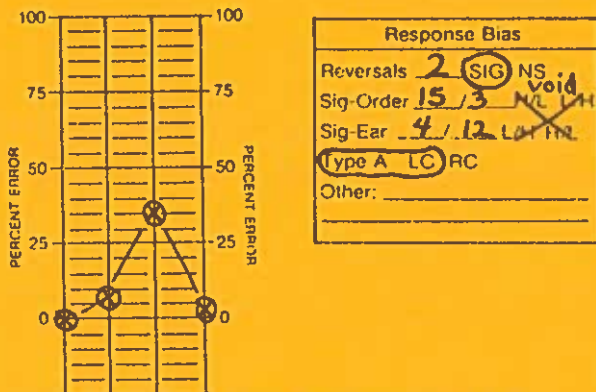


Fig.1. SSW-gram and response bias information for a 50-year-old patient who has difficulty hearing speech in a background of noise with entirely normal hearing.

The other central tests that were administered are as follows: Competing Sentence (CS), Filtered Speech (FS), Binaural Fusion (BF) and Dichotic Digits (DD). On the CS, she had a perfect score in the RE and 40% in the LE. Her response pattern was interesting for the LE. Not only is the score considerably below normal, but she took an extraordinary amount of time trying to figure out the sentence and usually got it wrong. On the FS test her score in the RE was 86% (normal) and 56% (abnormal) in the LE. The BF results were depressed in both ears. The score was 40% in the RE and 60% in the LE. On the DD she got 75% correct in the RE and 30% in the LE. When I was giving this test she said several time, "Oh, I can't do this, it is too confusing".

Like many people whom I see for CAP testing, there are other members of the family who have similar problems. This woman has a 17-year-old daughter who is failing in school. The daughter has always had academic difficulty and like her mother has a history of chronic middle ear disease.

What did we do before central testing? We could not have imagined that a person with normal hearing and excellent WDS would have listening problems and probably would have concluded that the patient was a kook.

Editor's Note--

Thanks for sharing this case, Darrel. It is a good one and contains some aspects that particularly interested me.

The Type A pattern that the patient demonstrated was quite dramatic. The Type A would likely classify the problem as an Integration disorder (Katz & Smith, 1991). Integration problems come in two types; the most common is type I. This is associated with the classic dyslexic in which the patient has severe dysfunction in reading and spelling (Katz, 1992) or at a minimum in spelling (Lucker, 1980). These individuals usually have auditory-visual integration problems, trouble with phonics, reduced scores on the Phonemic Synthesis test (especially in younger children) and often very poor handwriting.

One of the major integration signs on the SSW for both type I and type II cases is the inordinate delay in completing a response. This is designated by (XX), whereas the shorter, more typical delays are marked with (X).

The symptoms that were mentioned in this case were those associated with the Integration type 2 cases (i.e., memory, speech-in-noise and reading comprehension). What makes type 2 so interesting is that these are all signs that we see in another category of CAP disorder the Tolerance-Fading-Memory (TFM) problem (Katz & Smith, 1991).

My guess is that this less common type 2 is also associated with the region in and around the corpus callosum (or anterior commissure) as is the type 1 group, but more anteriorly, thus the cluster of characteristics associated with the anterior cerebral region. One distinguishing characteristic in this case was the delays, that are not common in those with pure TFM problems. I wonder if unlike the type 1 cases, that the type 2s tend to make errors when they have long delays (associated with their poor auditory memories), as in this patient on the SSW and CS tests. On the SSW 4 of the 6 inordinate delays were associated with eventual errors.

If you are interested in the categorization of CAP cases, we will have a session on this topic at the SSW Study Group in Atlanta (Nov. 21 @ 4 pm).

A second point of interest to me is that in general the Type A pattern voids any Order or Ear Effects, however, in type 1 cases they may be quite appropriate. For example, the Order H/L is associated with a rapidly fading (short-term memory). In this case it would give a correct impression (based on the patient's history). Until we are more sure how to handle this, it is probably well to continue to void the interpretation of the Order and Ear Effects in the presence of Type A.

In this particular case all of the primarily cerebral tests showed poor performance in the LE and good results in the right. The one test that is considered primarily a brainstem procedure was depressed bilaterally. I'm sure that this can vary a great deal from case to case, but I'm happy to see the consistency. Of course, you must know my bias by now, I am especially interested in tests that tell me what to do for the case, instead of simply indicating that there is a CAP problem.

Katz J & Smith PS, 1991. The SSW test: A 10 min look at CNS. Windows on Brain, NY Acad Sci, vol 620, 233-252.

Lucker J, 1980. Diagnostic significance of Type A pattern. Aud Hear Ed, 6, 21-3.

DEAR ACKIE

Dear Ackie:

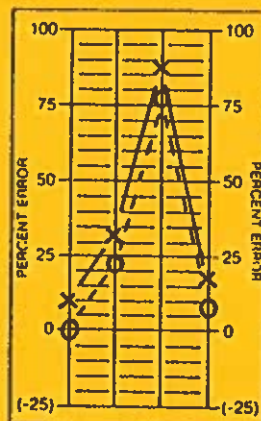
I found the following case to be interesting in light of Patti Johnstone's comment that we not forget adults (August 1990 issue). What do you think about the following case of a 69 year old woman who was diagnosed as having multiple sclerosis (MS)?

Signed: Darrel Feakes

Dear DF (to keep your identity secret):

Thanks for sending in this case (see Fig 1). There are many things that

Ackie could say about this case. However, if you expect it to be meaningful or intelligent, then I'm in some trouble. I would always look at the complaint, the history and the other audiometric data before saying much. But since I am loathe to say I don't know, let me jump in and see if what I say makes any sense.



Response Bias	
Reversals	— SIG NS
Sig-Order	27/32 H/L L/H
Sig-Ear	27/32 L/H H/L
Type A	LC RC
Other:	_____

First let me ask you how they know that this is MS? Okay, okay let's see what we have. The February 1990 issue of SSW Reports (p. 6) says that you need to differentiate between elderly people with significant hearing loss and those without. If a patient in her 60s has a speech average of better than 35 dB and less than a 20 dB difference between the ears, you have a reasonably good chance of distinguishing a brain lesion case from one who is simply showing "normal aging effects". While we don't know where the lesion is in this case, let's ask the question, "if this woman was seen by you, without knowing her diagnosis, would you be concerned and make the necessary referrals?"

The normal limits are RNC=3, RC=9, LC=14, LNC=3, REV=4, Ear/Ord difference =5. She fails on RC, LC and LNC, but just passes the Ear/Ord Effect criteria and she had no reversals. Therefore, she fails three aspects of the SSW. The "TOM" rule is that failure of only one criterion would still pass, but Two-Or-More failures would constitute failure on the test beyond what could be expected based on age alone. Therefore, the patient would be "correctly" identified. Now you might want to say, "don't forget the elderly". * * * * *